

Advancing Dentistry Through  
*Science*

The Journal of  
**EXCELLENCE**

---

---

July 2010



The Journal of Comprehensive Dentistry and Risk Assessment

## Inside the Circle of Excellence

---

### New CIs (formerly Mentors) as of the 2010 Symposium

David Cauble, DMD

Dan Demmings, DDS

Guillermo Galvan, DMD, MSD

Kim Larson, DDS

Chris Lindsey, DDS

Leah Patrick, DDS

Michael Sesemann, DDS

Robert K. Tang, DMD

### Existing Mentors who passed the 2009 Mentor Exam

Lee Anne Campbell, DDS

Bonnie Ferrell, DDS

Diana Germain, DMD, BSc

Robert Germain, DMD, BSc

Chris Mei, DDS

Chris Pickel, DDS

Greg Renyer, DMD

Linda Zimmerman, DDS

### New Mentors (formerly Graduates) who passed the 2009 Mentor Exam

Steve Acker, DDS

Joyce Bassett, DDS

William Ciao, DMD

Thomas Coburn, DDS

Lawrence Fujioka, DDS

Kenneth Harris, BDS, MFGDP(UK)

Derek Hopkins, DMD, MS, RDT, FRCD(C)

Kim Kutsch, DMD

Jeromy Peterson, DDS

### PRODUCTION TEAM

#### Editor in Chief

BETSY BAKEMAN, DDS

#### Editorial Board

NANCY HARTRICK, DDS

JEAN MARTIN, DDS, MPH

KEITH PHILLIPS, DMD, MSD

SANDY ROTH, BA

RENA VAKAY, DDS

#### Production and Manufacturing

AEGIS COMMUNICATIONS, LLC

---

### FOUNDER AND DIRECTOR

JOHN C. KOIS, DMD, MSD

---

### CENTER TEAM

#### Event Manager

KAREN KOIS

#### Office Manager

GRETCHEN SMITH

#### Finance Manager

ALYSSA SMITH

#### Course Manager

JODIE FOWLER

KARA MALONE

#### Operations Manager

LINNEA GASKINS

#### Technical Arts Specialist

BRENT ROSENBURGH

#### Registration Manager

SUZANNE ALLBEE

#### Clinical Research Specialist

YADA CHAIYABUTR, DDS, MSD, DSc

---

### CENTER ADVISORY BOARD

#### 2009–2010

PAT BEUG, DDS

ED BORIO, DDS

DAVE BROWN, DMD

DAN CLADER, DDS

MIKE PALMER, DMD

#### 2010–2011

ED BORIO, DDS

DAVE BROWN, DMD

JEFF GRAY, DDS

MIKE PALMER, DMD

*Excellence* is published annually in July. Copyright© 2010 by The Kois Center. Printed in the USA. *Excellence* is a registered trademark of The Kois Center. No part of this issue may be reproduced in any form without written permission from The Kois Center. For reprint information please contact The Kois Center.

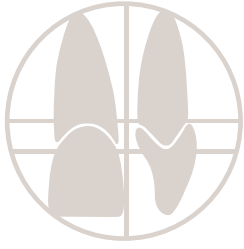Letters to the Editor: to comment on any of this issue's articles or features, please e-mail ebakeman@comcast.net or mail to Elizabeth Bakeman, DDS, 2757 Leonard NE, Grand Rapids, Michigan 49525. We reserve the right to edit all submissions.

The views and opinions expressed in the articles appearing in this publication are those of the author(s) and do not necessarily reflect the views or opinions of the editors, the editorial board, or the publisher. As a matter of policy, the editors, the editorial board, the publisher, and the university affiliate do not endorse any products, medical techniques, or diagnoses, and publication of any material in this journal should be construed as such an endorsement.

WARNING: Reading an article in *The Journal of Excellence* does not necessarily qualify you to integrate new techniques or procedures into your practice. The Kois Center expects its readers to rely on their judgment regarding their clinical expertise and recommends further education when necessary before trying to implement any new procedure.

# Table of Contents

VOLUME 1, NUMBER 4



## Curriculum Committee

Ric Shepherd, DDS  
David Cauble, DMD  
Esther Lee, DDS  
Howard Mizuta, DDS  
Tracy Tambosso, DMD  
Kim Larson, DDS  
Leon Hermanides, CDT

## Exam Committee

Lynn Blaisdell, DDS  
Mark Allen, DDS  
Mark Benavides, DDS  
Don Jayne, DDS  
Jim Polley, DDS  
Phil Timmins, DMD  
Paul VreNon, DDS

## Membership Committee

Dave Rice, DDS  
Doug Thompson, DDS  
Scott Eidson, DDS  
Jeff Bynum, DDS  
Jeff Grabel, DDS  
Chris Lindsey, DDS

## FEATURES

4 Inside the Circle of Excellence

6 Co-Discovery: Helping People  
Make Healthy Choices

Sandy Roth, BA

10 Peter Dawson—Turning Points

Sandy Roth, BA

15 Kois Center Speaks

39 Ask Yada

Yada Chaiyabutr, DDS, MSD, DSc

## CASE STUDY - ARCHIVES

16 Removable Prosthetics—  
A Ten Step Approach

Sid Parker, DMD

22 Using Indirect Restorations to Restore a  
Severely Worn Dentition and Create  
a Functional Occlusal “Home”

Ken Harris, BDS, MFGDP

28 A Second Chance—Implant-Retained  
Overdenture

Doug McMaster, DDS

34 Decreasing Functional Risk Utilizing  
Orthodontics and Restorative Dentistry

Mark Benavides, DDS

40 Orthodontic Extrusion and Implant Restoration  
to Manage Localized Advanced Bone Loss

Edward A. Borio, DDS

# Using Indirect Restorations to Restore a Severely Worn Dentition and Create a Functional Occlusal “Home”

A clinical case review



Ken Harris | BDS, MFGDP  
Private Practice  
Sunderland, United Kingdom  
[info@riveredge.co.uk](mailto:info@riveredge.co.uk)

## INTRODUCTION

With normal function, enamel can be expected to wear at a rate of about 0.01 mm per year.<sup>1</sup> Since occlusal enamel thicknesses range between 1 mm and 2.5 mm, dental enamel is expected to last a lifetime. Therefore, finding dentin exposed on occlusal surfaces raises suspicion that pathological wear has occurred. The dentist must determine if the wear is ongoing or now reflective of a stable condition that has not changed for years. If the process is ongoing, the change is often noticed by the patient or a spouse.

## CLINICAL CASE OVERVIEW

### *Patient History and Chief Complaint*

A 56-year-old man who was an attorney presented because his wife complained that she could no longer see his teeth when he smiled (Figure 1), and that the situation was worsening. A review of historical photographs showed normal tooth display 12 years earlier (Figure 2).

The patient maintained a busy legal practice and admitted neglecting his dental health. Basic reparative treatment, usually at emergency appointments, had been provided by different dentists over the years, with no recommendations provided for a long-term oral health strategy.

The present examination revealed a variety of older amalgam and composite restorations, as well as aging porcelain and gold full-coverage crowns; at least one crown was perforated occlusally. Tooth No. 5 had been extracted for orthodontic reasons. There was widespread occlusal wear, but the patient interview revealed a normal diet and no parafunctional habits, except clenching when driving. There was no history of nocturnal bruxism.

The patient was generally healthy and did not smoke. He admitted he had a hectic lifestyle and revealed a history of acid reflux symptoms of increasing severity over the last 5 years, for which he had not sought medical attention.

## DIAGNOSTIC OPINION

### Periodontal

The patient was classified as having mild AAP type II periodontitis. The radiographs revealed minimal bone loss, and all pocket depths were 2 mm to 3 mm deep, with minimal recession present. Generalized moderate gingivitis was present due to poor oral hygiene. The patient was a non-smoker and not a diabetic.

Risk: *Low*

Prognosis: *Good for all teeth*

### Biomechanical

The patient exhibited no active decay, and there was no evidence of carious lesions. The only tooth with a questionable restoration was tooth No. 11, which had a large, old, corroded filling with ditched and stained margins. Large restorations structurally compromised many posterior teeth (Nos. 3, 11, 13, 18, 20, 29, and 30), of which four were root filled (Nos. 11, 18, 29, and 30). The root fillings had been completed by an endodontist in London and were deemed acceptable.

The most significant factor noted at examination was tooth wear, which affected most biting surfaces in both the mandibular and maxillary arches (Figure 3 and Figure 4). Moderate wear (i.e., 2 mm lost) was observed on teeth Nos. 2, 3, 13, 20, and 21, with severe wear (i.e., 2 mm to 4 mm lost) noted on teeth Nos. 4, 6 through 11, and 22 through 28. The enamel on the patient's upper anterior labial surfaces had thinned by approximately 50% (Figure 5).

The loss of tooth structure had occurred in a classic cupping pattern, indicating that the exposed occlusal dentin was being lost more rapidly than the enamel. This finding suggested acid erosion, rather than parafunctional habits, as the cause of this structural loss. A diagnosis of gastric reflux from his physician confirmed this assessment.

A study of old photographs spanning 25 years suggested that a loss of vertical



Figure 1: A 56-year-old male patient presented because his wife noticed his teeth were "disappearing."



Figure 2: A photograph taken 12 years ago shows normal tooth length. The photograph suggested that tooth wear was a relatively recent event.

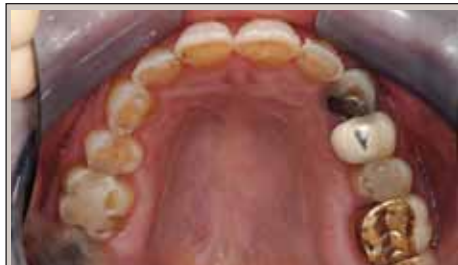

Figure 3: As a result of the widespread occlusal wear, significant dentin was exposed.

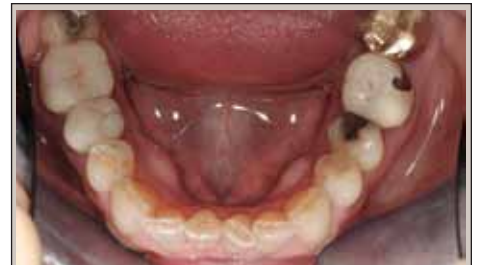

Figure 4: The cupping pattern of attrition on the exposed dentin of the lower incisors indicated an acid erosion problem, rather than a parafunctional grinding issue.

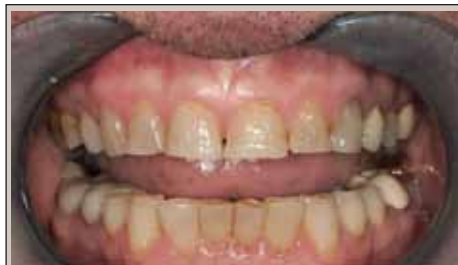

Figure 5: The labial enamel was reduced in thickness, almost exposing dentin in some areas.

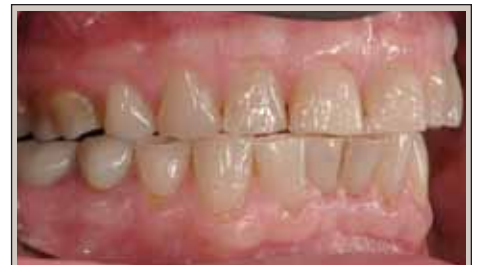

Figure 6: Lateral view of an occlusal plane worn flat, with little or no cuspal form remaining.

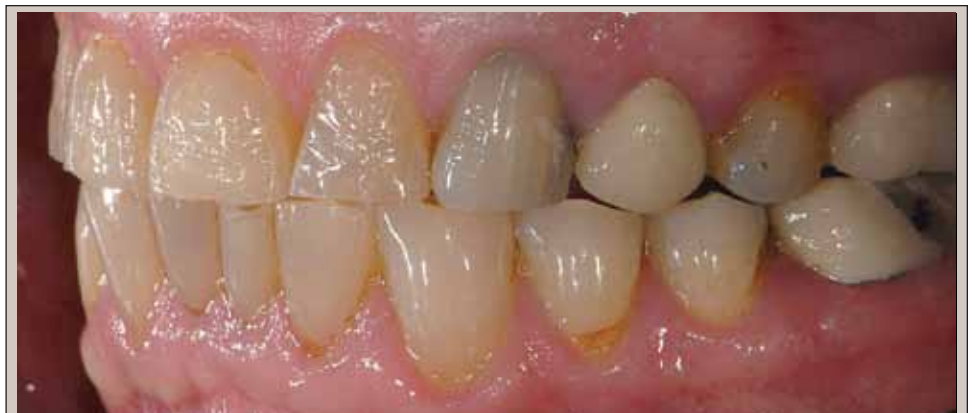

Figure 7: The absence of any specific cusp-to-fossae contacts as a result of the worn dentition made it difficult for the patient to efficiently find a "home" or maximum intercuspal position during function.

dimension had occurred during the last 12 years. This finding supported the patient's report of rapid tooth structure loss, since compensatory eruption would not have been able to keep pace with such rapid tooth wear.

**Risk: High**

*(while gastric reflux remained untreated)*

**Prognosis: Hopeless**

*(unless the gastric reflux was controlled);*

**Fair** *(once the reflux was controlled and the teeth restored)*

### **Functional**

Patient responses to questions regarding function and load testing suggested healthy temporomandibular joints. The only positive response to questions regarding function concerned the changing appearance of his teeth. Abfraction lesions were present (Nos. 21 and 28), but due to their small size, they were deemed insignificant. He had no history of nocturnal bruxism, but admitted to a clenching habit when driving.

Severe wear, as previously described, was present throughout the mouth. Not only was the individual cusp form obliterated, but the entire occlusal plane was worn flat overall, with no obvious "home" position (Figure 6 and Figure 7). A diagnosis of parafunction was considered and dismissed due to the cupping pattern of tooth structure loss and the negative history for bruxism given by the patient. In addition, the incisal edges would be expected to be worn flat in the case of a true nocturnal parafunctional habit.

The patient wore a Kois deprogrammer for four weeks. When deprogramming was confirmed, the mandible moved posteriorly, and a diagnosis of occlusal dysfunction was made.

**Risk: Moderate**

**Prognosis: Fair**

### **Dentofacial**

The patient's very low lip line completely hid his gingival margin. He specifically requested a natural "English" smile, rather than a synthetic "Hollywood" smile, although he did request some esthetic improvement. Gingival contours were acceptable and required no alteration. A slight upper midline discrepancy was noted, but because this did not concern the patient, correcting it was not a priority.

**Risk: Low**

**Prognosis: Good**

### **Medical**

A medical consultation was necessary to address the gastric reflux before starting any restorative treatment. There were no other significant medical findings and no medical contradictions to dental care.

The patient had loss of tooth structure due to occlusal dysfunction and acid erosion. Severe tooth surface loss from acid erosion led to dramatically shortened teeth, and reduced occlusal vertical dimension produced an edge-to-edge anterior occlusion. This loss had occurred over the last 5 to 10 years. When the gastric reflux was controlled, the patient was able to proceed with full-mouth reconstruction.

## **TREATMENT PLAN**

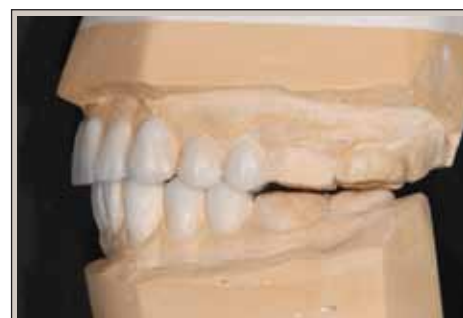The patient presented because his upper incisors were disappearing, and his motivation for treatment was esthetics. He accepted that unless the erosion was controlled, the prognosis for his teeth was hopeless. Therefore, compliance was not an issue.<sup>2</sup> The patient was referred to a physician for management of the gastric reflux disorder.

To satisfy the patient's esthetic objectives, the maxillary anterior teeth would be lengthened by approximately 2 mm, and the palatal surfaces restored to rebuild the lost tooth tissue. Cohesively retained porcelain crowns would be placed to restore the upper anterior teeth. Opening the bite also would allow the intra-arch horizontal position of the incisors to be repositioned from the current edge-to-edge scheme to a more conventional Class I relationship.

The worn maxillary posterior occlusal plane also would be lengthened by 2 mm to harmonize with the new incisal edge position. The existing posterior crowns would be replaced with cohesively retained porcelain crowns. The lower anteriors would be lengthened by 1 mm using adhesively retained porcelain veneers, since adequate enamel remained for bonded restorations. The worn mandibular posterior plane also would be raised by 1 mm using cohesively retained porcelain crowns.

The anterior restorations would slightly steepen the anterior guidance within the envelope of function and provide cuspid rise for immediate posterior disclusion in excursions. By re-creating proper occlusal

*"By re-creating proper occlusal anatomy, the posterior restorations would create a stable and easy to find "home" position, with lower buccal cusps fitting into the opposing fossae of the upper teeth."*



*Figure 8: In order to lengthen the incisors, the posterior segments were built up to maintain overall occlusal contact.*

anatomy, the posterior restorations would create a stable and easy to find “home” position, with lower buccal cusps fitting into the opposing fossae of the upper teeth.

To address the patient’s biomechanical needs, structurally compromised teeth would be prepared for full-coverage crowns. These included all endodontically treated teeth and all teeth in which the existing restoration isthmus width was greater than 50% of the intercuspal width of the tooth (Nos. 3, 5 through 14, 19 through 21, 29, and 30).<sup>3</sup> A foundation restoration would be placed on tooth No. 11 prior to crowning. Enamel-supported restorations would be placed for those teeth that were strong enough and exhibited enough enamel remaining (Nos. 2, 22 through 28).

## TREATMENT PHASES

### Phase I:

#### Deprogramming and Wax-Up

Routine preventive care and oral hygiene instruction were performed by the dental hygienist. A Kois occlusal deprogrammer was fitted and delivered to the patient.<sup>4</sup> After wearing the deprogrammer for one week, the patient was sufficiently deprogrammed to allow recording of an accurate centric relation (CR) record; the mandible had moved posteriorly into CR. A facebow record was made using a Kois Dentofacial Analyzer, and accurate study model impressions also were taken.

The patient models were mounted on a Panadent articulator in CR, using the facebow record and CR bite registration. Based on the previous estimate of additional incisor length necessary to achieve the patient’s esthetic vision, an increased vertical occlusal dimension was selected on the articulator.<sup>5</sup> The mounted models were sent to the laboratory for wax-up, and the patient was instructed to continue wearing the deprogrammer for three more weeks. This would ensure complete deprogramming by the preparation appointment, when the provisionals would be fabricated.

A functional wax-up was created at the new vertical dimension, with correct maxillary incisal edge position and length (Figure 8). To create a solid intercuspal “home,” the laboratory waxed the buccal cusps of lower teeth to fit precisely into the fossae of the upper teeth, with shallow guidance involving cuspid rise.

### Phase II: Restorative, Anterior

Three weeks after the bite records were taken, the patient presented for an all-day appointment. Upon evaluation, he was found to be completely deprogrammed, and no significant wear was noted on the deprogrammer platform.

The initial restorative phase began with the same-day preparation and temporization of 20 teeth (Nos. 3 through 13 and Nos. 20 through 29). During the morning session, teeth Nos. 3 through 13 were definitively prepared, using depth-cutting burs as described by Pascal Magne,<sup>7</sup> as well as the

wax-up, as a guide (Figure 9). Final silicone impressions were taken of the preparations, and bite records were made. The provisionals were fabricated using a suckdown stent of the wax-up. The occlusion was then refined in the provisionals, providing a correct, functional occlusion from the second bicuspid to second bicuspid at the new raised occlusal vertical dimension. With the provisionals in place, the unprepared molars were now out of occlusion. Composite resin was added to the occlusal surfaces of the molars to provide correct posterior occlusion on all 24 occluding surfaces. In the afternoon session, the lower teeth (Nos. 20 through 29) also were definitively prepared and provisionalized in a similar manner, and a final silicone impression was taken.

However, when preparing upper and lower arches at the same time, it is important not to lose the CR position created in the wax-up. Therefore, a careful process of “cross mounting” was utilized, which required specific details to be captured with

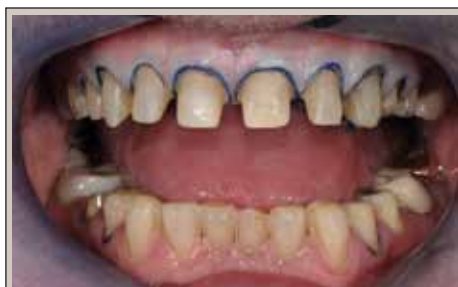

Figure 9: In a single visit, 20 teeth were prepared, and the upper and lower provisionals established a new vertical dimension of occlusion.

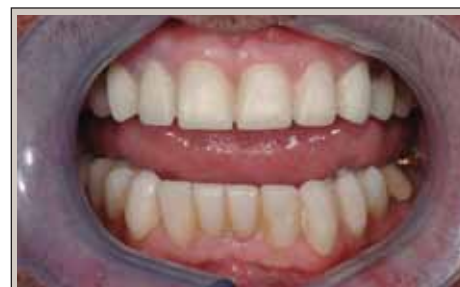

Figure 10: During a four-week trial period, the new occlusal pattern was successfully tested with the provisional restorations. The esthetics of the reconstruction also were finalized and approved over this period.

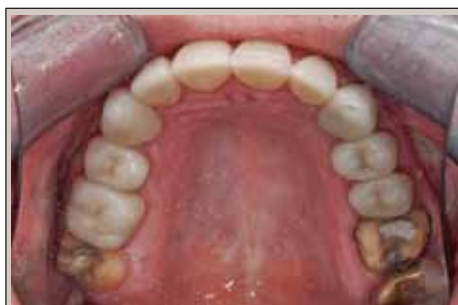

Figure 11: The four molars were prepared for porcelain restorations after the 20 anterior units were inserted.

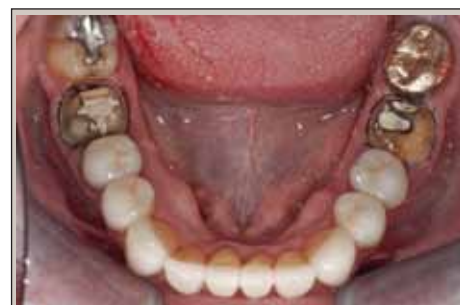

Figure 12: The lower molars were prepared for full-coverage crowns at the same appointment as the uppers.

interocclusal records during the preparation and provisionalization steps.

While the upper provisionals were off, the correct occlusal relationship was maintained by the composite occlusal surfaces that were established on the molars. Another interocclusal record was taken at this occlusal vertical dimension, with the upper preparations against the lower provisionals. This was carefully labeled “upper preparations to lower provisionals.” The upper provisionals were then fitted to the upper arch to again restore the occlusal pattern against the lower provisionals.

The same process was followed with the lower preparations and the upper provisionals; the molars held the correct occlusal relationship, and another interocclusal record was taken and carefully labeled “lower preparations to upper provisionals.”

A final interocclusal record was taken with all provisionals removed, and the occlusion was still maintained by the molars. This was labeled “upper preparation to lower preparation.” These four interchangeable interocclusal records were available for the laboratory to cross mount each set of models on the articulator in any combination.

The upper and lower provisionals were then recemented, and the occlusion was minimally refined. The patient wore the provisionals at the new occlusal dimension for a 4-week trial period. At the follow-up appointment, all provisionals were intact, the patient reported no issues, and he was satisfied with the esthetics (Figure 10). The laboratory, therefore, was instructed to fabricate the definitive porcelain restorations, using the provisionals as a template for their design.<sup>6</sup>

Silicone impressions then were taken of the upper and lower arch provisional restorations, in addition to a silicone interocclusal record, which was carefully labeled “provisional to provisional.”

Another all-day appointment was scheduled to definitively cement all 20 anterior restorations (Nos. 3 through 13 and Nos. 20 through 29). In the morning, the upper-arch core-supported (lithium disilicate) restorations (Nos. 3 through 13) were cohesively cemented simultaneously using a self-etching resin cement. The lower restorations, all of which also were fabricated from lithium disilicate glass, then were seated during the afternoon session at the same time that the enamel-supported restorations (Nos. 22 through 28) were cemented adhesively using a total-etch technique with a fourth-generation dentin adhesive and light-cured resin cement. The cohesively retained crowns (Nos. 20, 21, and 29) were cemented using a self-etching resin cement.

Each arch was isolated separately with a rubber dam, and the preparations were sandblasted prior to cementation. Once the restorations were fitted, an initial occlusal adjustment was completed to confirm that the “home” (P2) position and guidance (P3) were correct.

### **Phase III: Restorative, Posterior**

After the definitive anterior restorations were completed, the second phase of the restorative treatment involved restoration of the molars to the new occlusal position. In particular, one week after cementation, the patient was re-appointed for occlusal review and definitive preparation of the molars (Nos. 2, 14, 19, and 30).

At this follow-up appointment, all 20 indirect restorations were definitively occlusally refined in CR to establish the correct intercuspal “home” position (P2) using Shimstock and thin articulating paper. The guidance, or “pathway” (P3) was evaluated using 200- $\mu$ m horseshoe paper. The paper

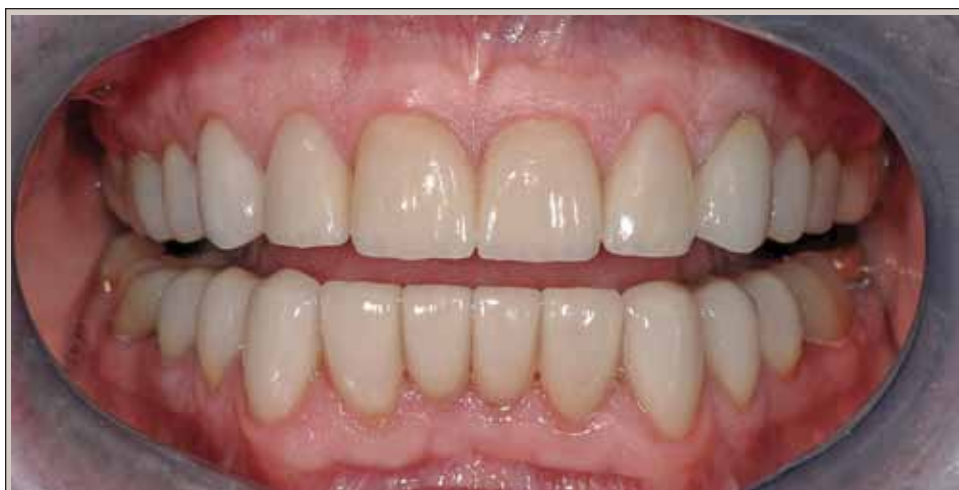

Figure 13: The restoration of the teeth involved a combination of cohesively retained porcelain crowns and adhesively retained porcelain restorations. The biomechanical requirements of each tooth dictated the type of restoration that would best serve the patient's interest.

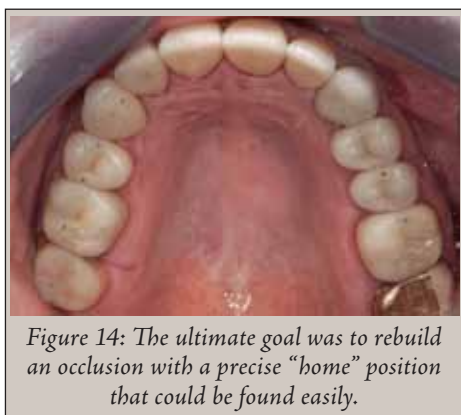


Figure 14: The ultimate goal was to rebuild an occlusion with a precise “home” position that could be found easily.

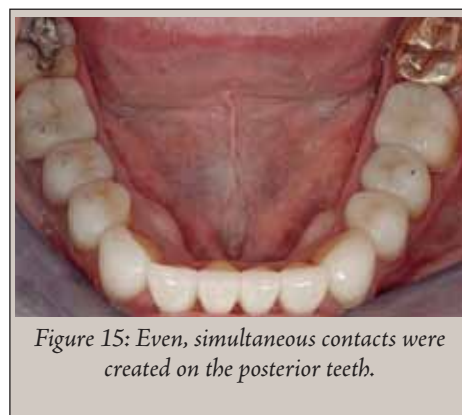


Figure 15: Even, simultaneous contacts were created on the posterior teeth.

revealed only very slight streaks on the incisors, indicating a potential minimal infringement of the pathway of closure created by the palatal bulk of the new maxillary crowns; these were easily polished away.

Teeth Nos. 2, 14, 19, and 30 then were prepared for porcelain restorations (Figure 11 and Figure 12), impressions and CR bite records were taken, and facebow records were obtained using the Kois Dentofacial Analyzer. The laboratory was instructed to fabricate the posterior restorations to the same occlusal “home” position as the other teeth.

Three weeks later, the provisional molar restorations were replaced with definitive porcelain restorations. The porcelain crowns for teeth Nos. 14, 19, and 30 were cemented with a self-etching resin cement, and the enamel-supported onlay (tooth No. 2) was cemented adhesively with a light-cured resin cement, representing the completion of a total of 24 opposing units within the newly established occlusal “home” position (Figure 13). One week later, the occlusion was reviewed and refined again (Figure 14 and Figure 15).

The patient presented for a 3-month follow-up appointment to review and refine the occlusion, as needed. Once again, “home” (P2) was checked using Shimstock and thin articulating paper, and guidance (P3) was verified with the horseshoe paper. Slight adjustment at P2 was necessary to re-establish “home” (P2), but the guidance (P3) required no adjustment (Figure 16 and Figure 17).

Regular hygiene visits every 6 months and an annual occlusal examination were recommended to the patient. However, his busy lifestyle may prevent regular attendance. He is aware that he must continue taking gastric medication, and that his conscious clenching habit may return.

## CONCLUSION

Periodontal risk remains low, with good prognosis. Biomechanical risk was initially high with a hopeless prognosis. By

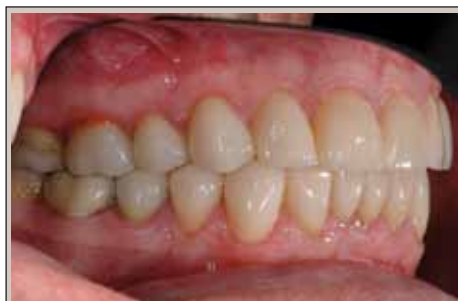

Figure 16: The restored occlusal plane was rebuilt in harmony with dentofacial parameters and functional requirements.

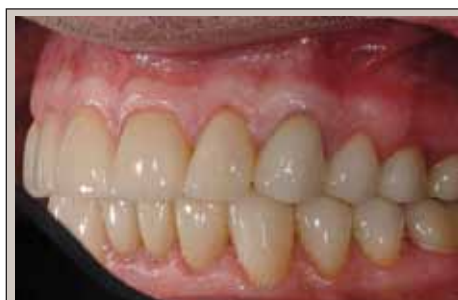

Figure 17: Lateral view of the restored occlusal plane shows the distinct cuspal form, which allows for precise occlusal contact.



Figure 18: The posttreatment smile reveals the patient is satisfied with the esthetics of his new “English smile.”

controlling the gastric reflux and placing indirect restorations, the risk has been reduced to moderate, and the prognosis is fair. Functional risk continues to be moderate. The creation of a stable and repeatable P2 “home” position with appropriate guidance lessened this patient’s risk of future functional problems and improved his functional prognosis. However, due to his history, he cannot be classified as low risk.

Dentofacial risk remained low, with good prognosis. Esthetically, the patient and his family were very happy with his new smile (Figure 18). He was greatly relieved that he did not end up as an Englishman with an American smile.

## REFERENCES

1. Lambrechts P, Vanherle G, Vuylsteke M, Davidson CL. Quantitative evaluation of the wear resistance of posterior dental restorations: a new three-dimensional measuring technique. *J Dent.* 1984;12(3): 252-267.

2. Gregory-Head B, Curtis DA. Erosion caused by gastroesophageal reflux: diagnostic considerations. *J Prosthodont.* 1997;6(4): 278-285.
3. Geurtsen W, Schwarze T, Günay H. Diagnosis, therapy, and prevention of the cracked tooth syndrome. *Quintessence Int.* 2003;34(6):409-417.
4. Jayne D. A deprogrammer for occlusal analysis and simplified accurate case mounting. *J Cosmetic Dentistry.* 2006;21(4):96-102.
5. Kois JC. Occlusal vertical dimension: what is the controversy? *Compend Contin Educ Dent.* 1997;18(12):1164.
6. Armellini D, von Fraunhofer JA. The shortened dental arch: a review of the literature. *J Prosthet Dent.* 2004;92(6): 531-535.
7. Magne P, Magne M. Use of additive waxup and direct intraoral mock-up for enamel preservation with porcelain laminate veneers. *Eur J Esthet Dent.* 2006; 1(1):10-19.



**KOIS CENTER, LLC**

1001 Fairview Ave N, Suite 2200 • Seattle, WA 98109

Tel (206) 621-5310 • Fax (206) 621-7609

[WWW.KOISCENTER.COM](http://WWW.KOISCENTER.COM)